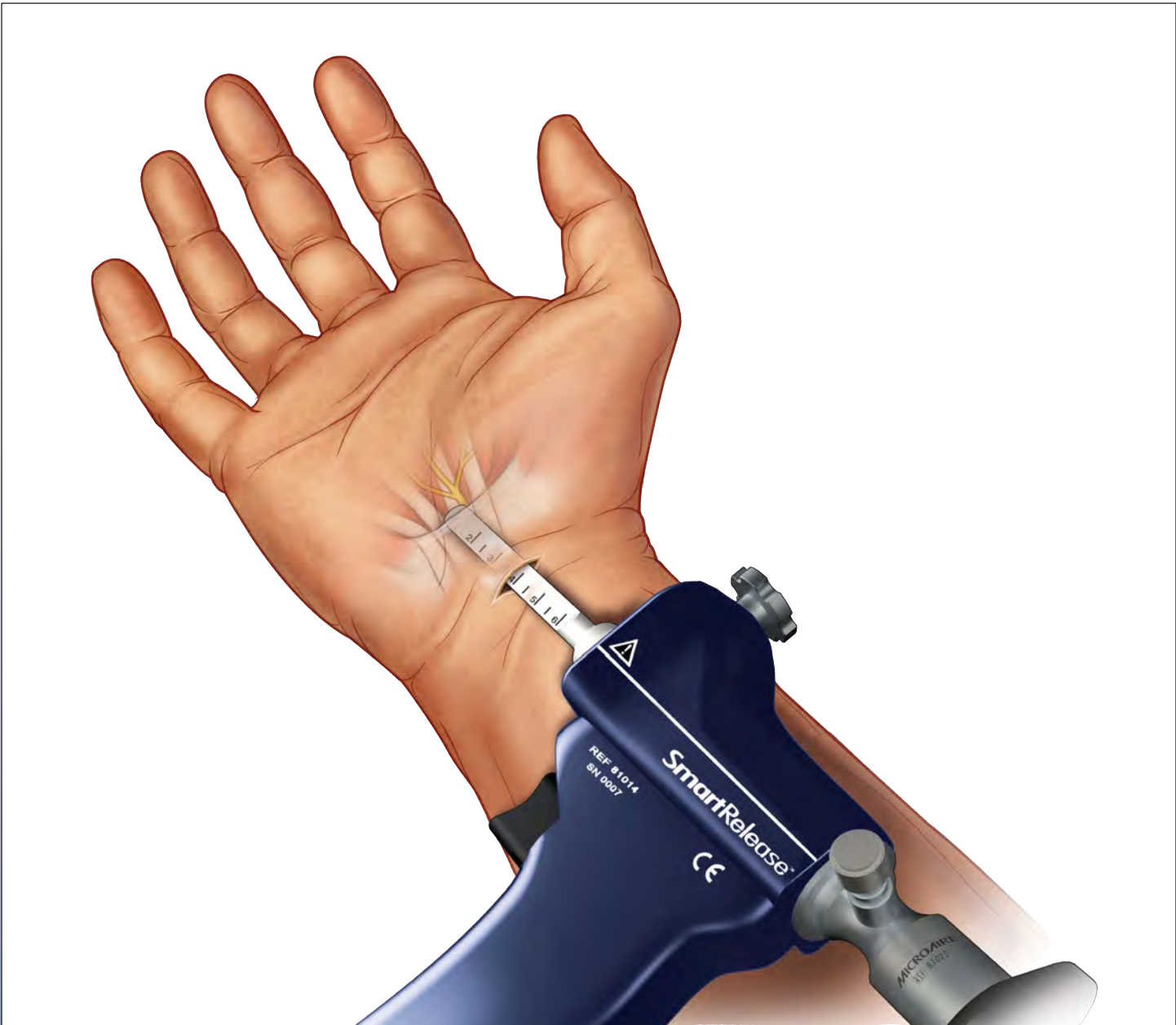

SmartRelease™ ECTR

Endoscopic Carpal Tunnel Release

Surgical Technique

Surgical Technique

SmartRelease™
Endoscopic Carpal Tunnel Release **ECTR**

MICROAIRE®
For Surgery. For Life.™

Indications and Contraindications

- **Indications:** The MicroAire Carpal Tunnel Release System is for use in patients diagnosed with carpal tunnel syndrome that is not associated with, or secondary to, any other known pathology (i.e., “idiopathic” carpal tunnel syndrome). Preoperative x-rays of the wrist, including a carpal tunnel view, are recommended to aid in the diagnosis of associated pathology (i.e., calcific tendonitis, fracture of the hook of the hamate). This device is indicated solely for releasing the transverse carpal ligament (flexor retinaculum).
- **Contraindications:** The MicroAire Endoscopic Carpal Tunnel Release System is not intended for use in patients with known abnormalities of their wrist (carpal tunnel), including distal radial deformities, rheumatoid and other synovitis.

* The MicroAire Carpal Tunnel Release System uses a dry procedure. No fluid or gas should be introduced into the carpal tunnel during this procedure.

Warnings

- The surgeon is specifically advised not to use the instrument to explore and/or treat any structure other than the transverse carpal ligament within, or outside of, the carpal tunnel. Failure to heed this warning can lead to damage to the median or ulnar nerve, flexor tendons or superficial palmar arterial arch.
- If the surgeon is unable to clearly visualize an ulnar “strip” of the transverse carpal ligament with a definite distal margin (which is typically characterized by a transition from ligament to fat), the blade assembly should be withdrawn and the procedure should be converted to another carpal tunnel release procedure.
- If the surgeon has any questions or concerns regarding patient anatomy, the surgical approach or instrument function—or if the view is less than adequate—the instrument should be withdrawn and the procedure converted to another carpal tunnel release procedure.
- Failure to follow the proper training and surgical technique can result in permanent injury to the patient. Endoscopic release of the carpal tunnel using the MicroAire® SmartRelease™ ECTR should not be attempted until the surgeon has been trained at a MicroAire-sponsored workshop. This training requires thorough familiarity with this *Surgical Technique*, the *Instructions for Use* and gaining hands-on experience with a trained surgeon who is experienced with the device. The procedure should be performed on cadaveric specimens before initial use. Operating room staff should thoroughly review the MicroAire® SmartRelease™ ECTR® *Instructions for Use* (REF: IM-ECTR-IFU) prior to set up of this system.

Definitions

- **NOTE:** Indicates the easiest means of carrying out techniques.
- **CAUTION:** Indicates special procedures or precautions that must be followed to avoid damaging the system instrumentation.
- **WARNING:** Indicates that the safety of the patient and hospital personnel could be involved.

Table of Contents

Indications / Contraindications.....	i
Warnings / Definitions	i
Introduction	1
Instrumentation	2
Troubleshooting Guide for Fogging	3
Surgical Setup	4-5
Anesthesia	5
Operative Technique	6-13
Step 1	
Making the incision and creating a flap	6
Step 2	
Elevating the U-shaped flap	7
Step 3	
Preparing a path	7
Step 4	
Introducing the blade assembly	8
Step 5	
Defining the distal end of the ligament	9
Step 6	
Incising the transverse carpal ligament.....	9-11
Step 7	
Inspecting the incised ligament	12
Step 8	
Releasing the forearm fascia.....	13
Step 9	
Closing and dressing the wound and wrist ...	13
References.....	13

Contents ©2011

MicroAire Surgical Instruments.

This document is protected from any form of unauthorized reproduction, duplication or distribution.

Introduction

Traditionally, a patient treated surgically for carpal tunnel syndrome could expect significant recovery time away from work due to the surgical wound in the palm and heel of the hand. When the carpal tunnel is released endoscopically with the MicroAire® SmartRelease™ ECTR, clinical results indicate that postoperative morbidity is improved and time away from normal activities and full employment are reduced by as much as 46 percent.¹ The safety of this device has also been documented in a large clinical study involving over 1,000 cases in a 63 - multicenter study.² The results of this study showed minimal complications.

Comprised of an endoscope and a handpiece that holds an elongated, disposable blade assembly, the MicroAire® SmartRelease™ ECTR connects to any standard video camera and light source. The surgeon introduces the blade assembly into the carpal tunnel through a limited incision in the wrist flexor crease.* Viewing the deep side of the transverse carpal ligament (flexor retinaculum) through a window at the tip of the instrument, the surgeon elevates the blade to cut the ligament as the instrument is withdrawn.

This Surgical Technique is provided as an educational tool and clinical aid to assist medical professionals in the proper protocol for the MicroAire® SmartRelease™ ECTR endoscopic carpal tunnel release instrumentation. For safe and effective use, surgeons must possess a thorough knowledge and understanding of wrist anatomy and the endoscopic technique using the MicroAire® SmartRelease™ ECTR System. Instructional videotapes and cadaver workshops are available through MicroAire Surgical Instruments.

Those considering using the MicroAire® SmartRelease™ ECTR System should only do so after successfully completing MicroAire's required surgical training as well as the relevant training mandated in the professional guidelines of any pertinent hospital, institution or society. For training dates and locations, visit www.microaire.com

Failure to follow the Surgical Technique may result in permanent injury to the patient. If, while performing this technique, any problems should arise, such as anatomical anomalies, inadequate visualization, inability to identify anatomy or questions concerning technique or instrumentation, the surgeon should abandon the endoscopic carpal tunnel release and convert to another carpal tunnel release procedure.

These pages are not intended to provide medical advice or physician instruction on the appropriate use of products produced or supplied by MicroAire Surgical Instruments, its affiliates, related companies, or its licensors or other partners.

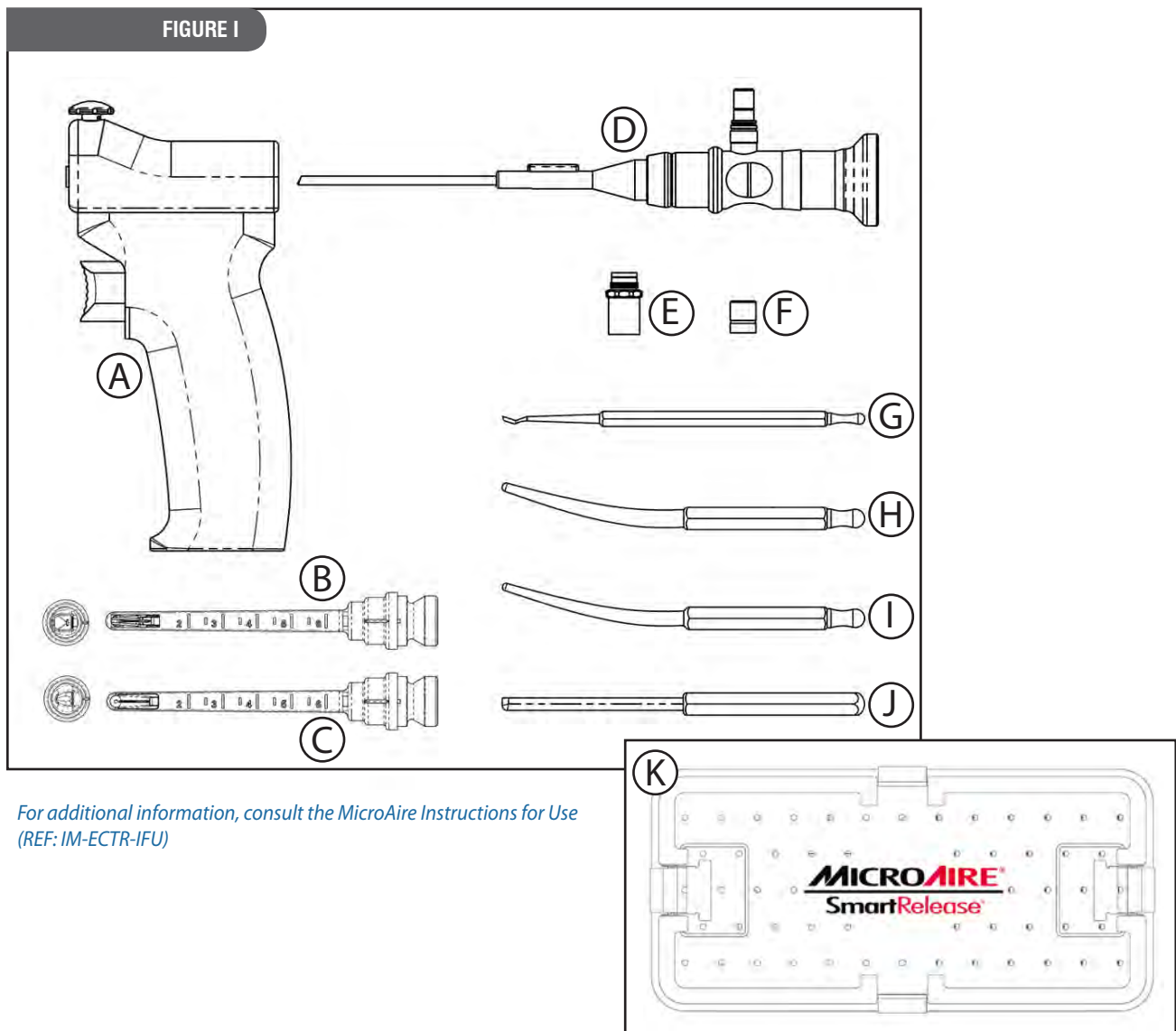
*The MicroAire® SmartRelease™ ECTR uses a dry procedure.
No fluid or gas should be introduced into the carpal tunnel during this procedure.



INSTRUMENTATION

SmartRelease™ ECTR Instruments and Accessories

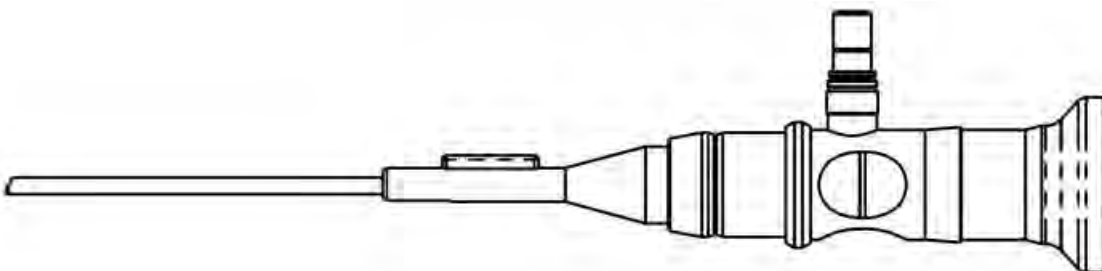
- | | |
|---|------------------------|
| A) SmartRelease™ Aluminum Handpiece | REF 81014 |
| B) ECTR Disposable Blade Assembly | REF 81010-1 or 81010-6 |
| C) ECTR Disposable SlimLine Blade Assembly | REF 82020-1 or 82020-6 |
| D) 3.0mm Eyepiece Autoclavable Endoscope | REF 81025 |
| E) Endoscope Light Post Adapter, Wolf® | REF 81152 |
| F) Endoscope Light Post Adapter, Storz® | REF 81151 |
| G) Hamate Finder – Coequal to Disposable Blade Assembly | REF 81061 |
| H) Hamate Finder – Small | REF 81026 |
| I) Hamate Finder – Medium | REF 81027 |
| J) Synovium Elevator | REF 81029 |
| K) Instrument Sterilization Tray | REF 81040 |



TROUBLESHOOTING GUIDE FOR FOGGING

In order to quickly identify the source of the fogging problem and formulate the appropriate solution, you should:

1. Assemble the system before the surgeon makes the skin incision to start the procedure.
2. Turn on the camera, light source and monitor. White balance using a white sponge and then lay a blue or green towel on the window using the fabric of the towel to set the light intensity and to focus on the mid and distant portion of the window.
3. Observe for any sign of fogging.



ISSUE	PROBABLE CAUSE	PREVENTATIVE MEASURES	SUGGESTED SOLUTION
Fogging appeared before inserting in to carpal tunnel	Moisture inside camera scope interface	Disassemble and dry endoscope and camera lenses with alcohol or anti-fogging agents. (See Note 1)	<ol style="list-style-type: none"> 1. EtO or stream sterilize instead of soaking. 2. Using anti-fogging agents to dry before assembling. 3. Soak scope with camera attached. 4. Keep system warm by turning on light source.
	Water trapped between plastic eyepiece and scope lens	Use a sterile cotton swab to soak up water around the gap between the scope lens and plastic eyepiece.	Thoroughly dry the scope-camera coupler interface with a cotton swab after soaking.
Fogging after inserting in to carpal tunnel	Condensation due to temperature difference between the scope and patient's tissue.	<ol style="list-style-type: none"> 1. Leave inside tunnel until scope warms to body temp. 2. Dip scope tip in to warm saline and wipe dry. 	<ol style="list-style-type: none"> 1. Connect to light source to pre-warm. 2. Rinse scope with warm saline after soaking.
	Excess fluid inside the carpal tunnel	Soak up excess fluid with sterile cotton swab.	Avoid injecting anesthetics in to the carpal tunnel.
Fuzzy or leave persisting	Damaged scope	Return scope to MicroAire Service	Always protect the scope when not in use.

Note

Beware of contamination caused by disassembling the camera and the scope in the same sterile field if they have been attached together during soaking.

For additional information, consult the *MicroAire Instructions for Use* (REF: IM-ECTR-IFU)

SURGICAL SETUP

Surgical Setup

Two physical considerations dictate the best surgical setup: the surgeon's orientation with respect to the video monitor and the patient's operative hand. The surgical suite should be set up to offer the surgeon the best view of the video monitor. The surgeon should be able to easily shift his/her gaze upward from the surgical field to the video image.

The patient is positioned supine on the operating room table with the arm abducted 75-80 degrees. A tourniquet should be used in this procedure. Care should be taken to avoid pressure on the ulnar nerve at the elbow. Sterile draping leaves the arm, elbow, forearm, wrist and hand distal to the tourniquet fully exposed to permit exsanguination of the forearm and hand. The hand, wrist, forearm and the arm proximal to the elbow should be completely exsanguinated using an Esmark bandage; venous blood trapped distal to the tourniquet will cause a locally anesthetized patient premature pain.

The surgeon's hand, when holding the instrument, should naturally align the blade assembly so that it points from the ulnar side of the carpal tunnel to the base of the ring finger. This course is anatomically optimal for avoiding injury to the median nerve. Surgeons who are ambidextrous using the endoscope generally take the axillary position when performing either a left or right carpal tunnel release (holding the instrument in their right hand for a right carpal tunnel and in their left hand for a left carpal tunnel). Those favoring right-handed use will usually prefer a position in the axilla for a right carpal tunnel release and cephalic position for a left release.

The patient's hand is positioned, palm up, on a hand table equidistant between the surgical assistant and the surgeon. The surgeon should be able to easily view the monitor over the assistant's right or left shoulder. If desired, a scrub nurse can sit at the end of the hand table. A movable cart, which holds the monitor, the light source and camera electronics, is placed behind and with the monitor slightly to one side of the surgical assistant. The fiber-optic cable is clipped to a drape at the patient's shoulder.

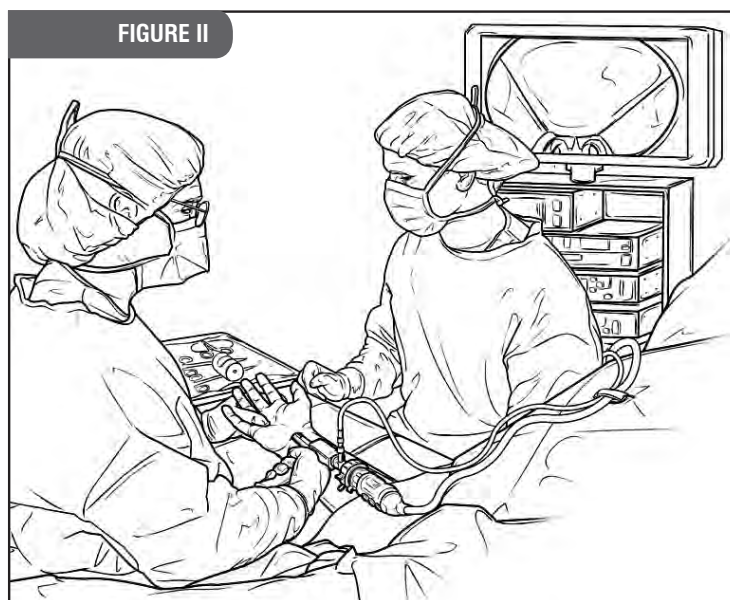
To conduct a carpal tunnel release procedure using the MicroAire® SmartRelease™ ECTR, the sterile field should include:

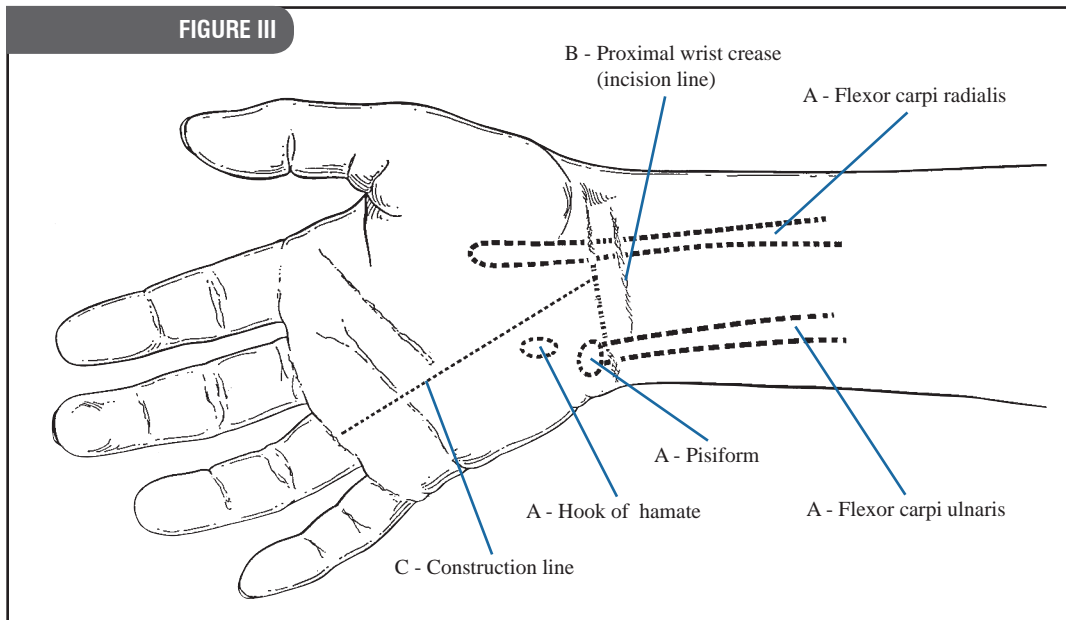
- 2 double-pronged skin hooks
- 2 Ragnell right angle retractors
- 1 pair of tenotomy scissors
- 1 Sterile skin marking pen
- 1 small hamate finder*
- 1 synovium elevator *
- 2 Senn rake retractors
- 1 Adson tissue forceps with serrated tips
- 1 scalpel, #15 blade
- 1 standard hamate finder*
- 1 Blade-shaped coequal hamate finder (optional)*

*(Included with MicroAire® SmartRelease™ ECTR)

Important

In the surgical suite—before the patient is brought into surgery with the intention of performing the procedure endoscopically—the MicroAire® SmartRelease™ ECTR should be fully assembled and checked for correct operation, which includes blade elevation and retraction and a clear video image. The equipment, including the instruments and video monitor, should be positioned relative to the operating table and surgeon's position after the extremity is prepped and draped.





Before elevation of the tourniquet, it is recommended that the surgeon mark key anatomical landmarks on the patient's hand using a sterile skin marking pen: the tendons of the flexor carpi ulnaris and flexor carpi radialis, pisiform bone and hook of the hamate. [Figure III]

In addition, the surgeon should select and mark the intended incision line at a wrist flexion crease.

Finally, the surgeon should draw a construction line from the middle of the wrist flexion crease to the palmar base of the ring finger. This line should pass radial to the mark over the hook of the hamate.

Anesthesia

A general or regional anesthetic is strongly recommended. Local anesthetic increases tissue fluid, which can obscure endoscopic viewing and cause lens fogging. **Only when the surgeon has gained experience with the surgical approach and instrumentation should the procedure be performed using local anesthesia.**

When local anesthesia is used, the tourniquet is elevated and a volume of one percent Lidocaine without epinephrine is injected intracutaneously/subcutaneously in the wrist flexion crease, extending from the flexor carpi ulnaris to the flexor carpi radialis. Use the least amount of local anesthesia possible. Avoid injecting/adding local anesthesia deep to the forearm fascia as it will extend into the carpal tunnel, compromising the endoscopic view of the transverse carpal ligament.

Important

When beginning the local anesthesia, it is important that the patient receive minimal or no sedation. A sedated patient may move abruptly in response to discomfort when instrumentation is being introduced into the tunnel. Frequently, local anesthesia requires support with other anesthetic agents as prescribed by the anesthesiologist or surgeon.

To help minimize the opportunity for patient injury under local anesthesia, it is very important that:

- (1) *The surgeon and assistant be prepared to manually restrain any sudden movements by the patient; and*
- (2) *The instruments (i.e. synovium elevator, hamate finders and blade assembly) should be passed down the carpal tunnel in a manner that will help avoid injury to the median nerve (and other carpal tunnel structures) if the patient moves suddenly.*

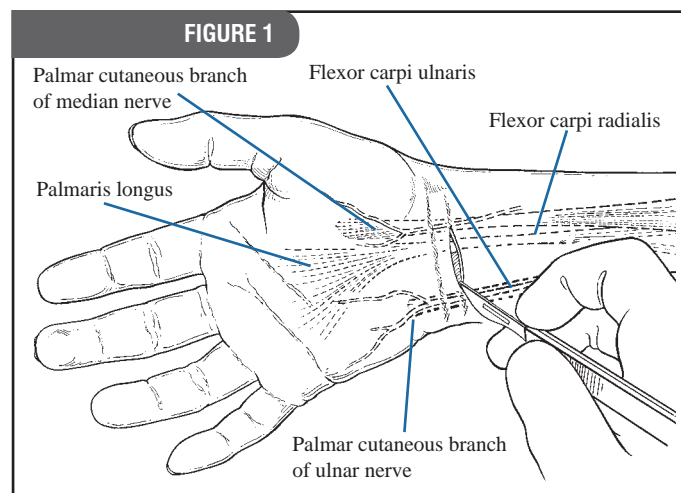
STEP 1

Making the incision in a wrist flexion crease.

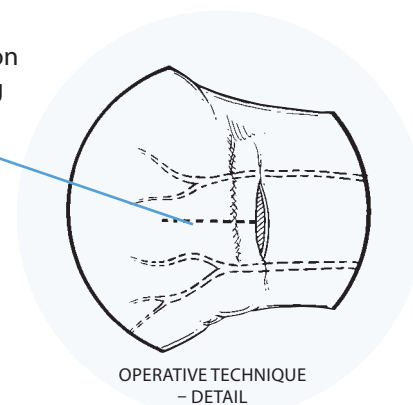
Choose a wrist flexion crease that is just proximal to the crease that separates the glabrous skin of the palmar surface of the hand and the “mobile” skin of the forearm. Make a 2 - 3cm transverse incision between the tendons of the flexor carpi radialis and the flexor carpi ulnaris. Take care to stop short of the subcutaneous tissues and their cutaneous nerves. Use a spreading longitudinal dissection to protect these nerves and expose the forearm fascia.

Note

- If faced with choosing between two otherwise suitable wrist flexion creases, the more proximal crease is technically easier to use because of less subcutaneous fat.
- With experience, surgeons may choose to use a smaller incision, centered at the middle of the wrist, between the flexor carpi ulnaris and the flexor carpi radialis.
- If necessary, the transverse incision across the wrist can be extended proximally and distally, perpendicular to the transverse incision to convert to an open release procedure (refer to inset).
- The transverse incision may overlie the palmar cutaneous branch of the median nerve. If the palmar cutaneous branch of the median nerve is visualized in the radial side of the wound, it can be gently isolated and retracted.



If necessary, skin incision may be extended using guidelines



STEP 1-A

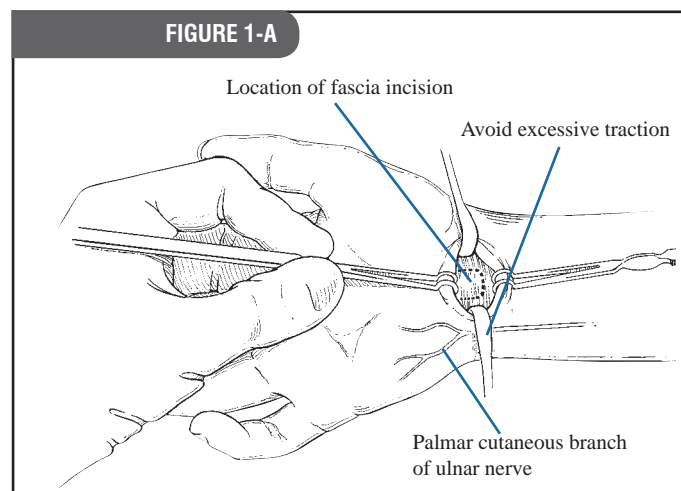
Making the incision, continued.

Make a U-shaped incision in the forearm fascia, creating a rectangular flap distally based on the transverse carpal ligament. Preparing and elevating this U-shaped flap from the underlying finger flexor synovium (ulnar bursa) allows the surgeon to develop a plane between the synovium and the deep side of the transverse carpal ligament.

Warning

The median nerve is immediately beneath this flap—use caution.

Avoid excessive traction on the ulnar neurovascular bundle, which may result in ulnar nerve neuropraxia.

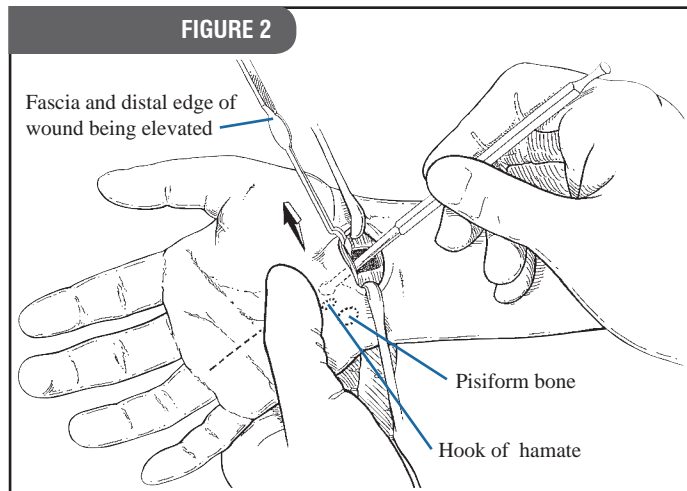


STEP 2

Elevating the U-shaped flap of forearm fascia and creating a path into the carpal tunnel.

While vertically elevating the flap of forearm fascia in a palmar direction, use tenotomy scissors to gently spread and separate the forearm fascia from the synovium of the ulnar bursa. Position the synovium elevator in line with the base of the ring finger, radial to the hook of the hamate. Using the synovium elevator, feel the roughness (“washboard effect”) of the transverse fibers of the transverse carpal ligament. Continue to separate the ulnar bursa (synovium) distally until its tip is palpable at the distal end of the carpal tunnel.

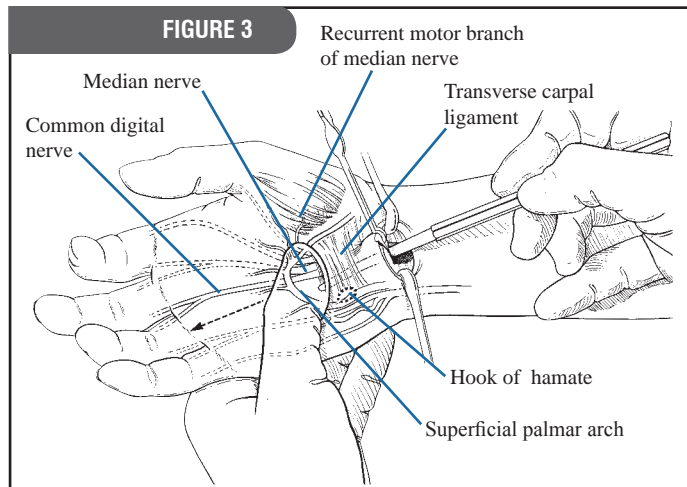
To optimally orient the synovium elevator with the deep side of the transverse carpal ligament, it is recommended that the surgeon hold the patient’s hand with the opposite (non-instrument) hand. The position of the patient’s wrist in the flexion-extension plane can then be adjusted.



STEP 3

Preparing a path for the instrument.

Use the small hamate finder to create a path for the blade assembly. While aiming at the base of the ring finger and holding the wrist in slight extension, gently pass the hamate finder distally down the ulnar side of the tunnel, hugging the hook of the hamate until the finder’s curved tip can be palpated subcutaneously as it exits the carpal tunnel. One or two passes is sufficient to create a path. Use the standard or blade shaped hamate finder for larger hands.



STEP 4

Introducing the blade assembly into the carpal tunnel.

Blade extension and retraction should be checked before insertion into the patient's hand.

Holding the patient's wrist in slight extension, insert the blade assembly into the carpal tunnel, pressing the viewing window snugly against the deep side of the ligament. While aiming at the base of the ring finger, advance the instrument distally, hugging the hook of the hamate to assure an ulnar course.

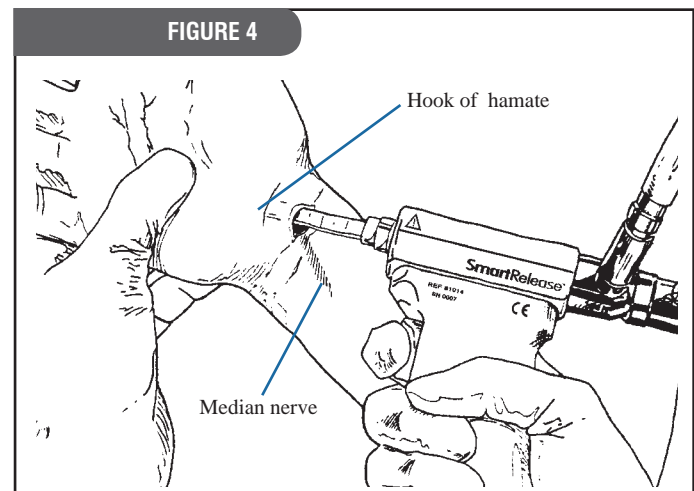
Note

To optimally orient the window of the endoscope with the deep side of the transverse carpal ligament, it is recommended that the surgeon hold the patient's hand with the opposite (non-device) hand. The position of the patient's wrist in the flexion-extension plane can then be adjusted as needed to view the entire length of the transverse carpal ligament.

Using the thumb of the non-device hand, the surgeon can palpate the tip of the blade assembly and hold the overlying tissues against the viewing window such that it is snugly apposed to the deep side of the ligament prior to, and during, blade elevation and subsequent cutting.

The disposable blade assembly is marked with a centimeter scale for surgeons who wish to integrate their knowledge of surface anatomy with the actual endoscopic view. This scale serves as a relative guide of the blade assembly's depth of insertion so that the surgeon can determine by direct measurement where the elevated blade will cut into the transverse carpal ligament.

To avoid injury to the median nerve and flexor tendons, during the cutting stroke it is imperative that the flat surface of the blade assembly be pressed and held snugly against the deep side of the transverse carpal ligament.



STEP 4-A

Introducing the blade assembly, continued

Blade assembly crosses over and superficial to the median nerve at the level of the skin incision.

Note

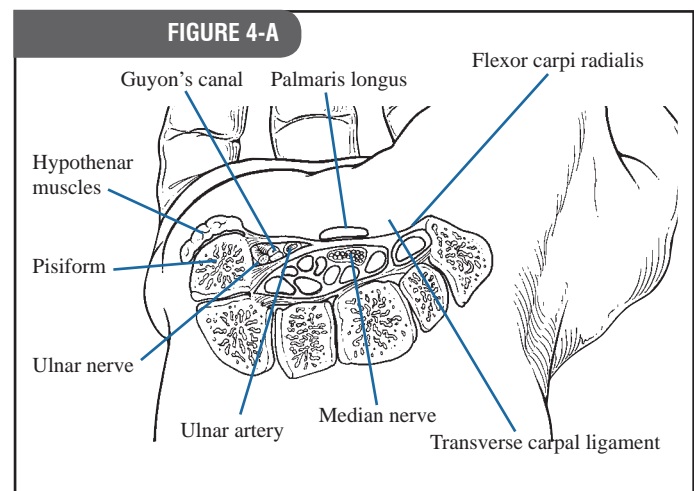
Be sure to positively identify the proximal end of the carpal tunnel (differentiating it from Guyon's canal) before inserting the blade assembly. Guyon's canal is superficial to the ulnar side of the carpal tunnel. A good double check: When inserting the blade assembly, be sure the space (canal) contains synovium. To check, move the patient's fingers passively for confirmation as the synovium, and to a lesser extent the median nerve, moves proximal and distal with the finger flexor tendons.

Caution

Do not attempt to use this device to explore the carpal tunnel. This device is designed exclusively for viewing the deep side of the transverse carpal ligament. Using the blade assembly as a probe or lever may cause severe injury to the patient and can damage the scope's optical train or break the blade assembly.

Note that the proximal extent of Guyon's canal (just distal to the skin incision) is variable in its radial extent.

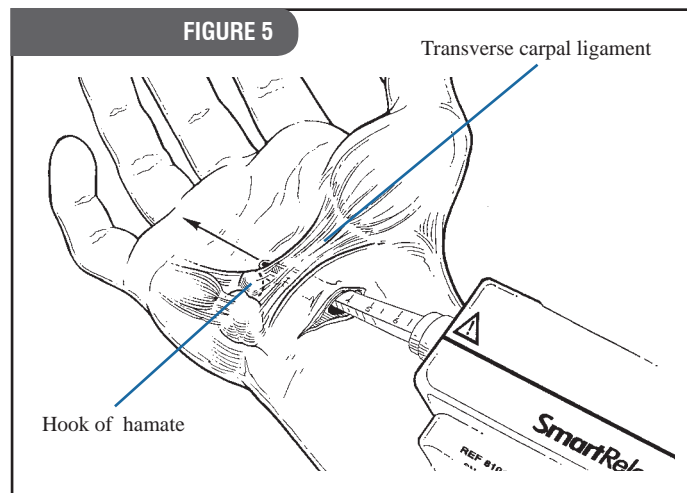
In an occasional patient, the radial extension of the "roof" of Guyon's canal (the volar carpal ligament) may be confused with the antebrachial fascia or the transverse carpal ligament. Correct entry occurs under a fascial plane that covers finger flexor synovium.



STEP 5

Defining the distal end of the transverse carpal ligament.

Use a sufficient number of proximal-to-distal passes to accurately define an ulnar “strip” of the transverse carpal ligament. Transverse fibers of the ligament should be visible within this strip. Palpating with the thumb, define the distal margin of the ligament at its junction with a pad of fat and align the point of entry markers at this junction.

**Note**

The fat typically overlaps the deep side of the ligament’s distal margin by a couple of millimeters.³ This contrasts with the occasional patient that lacks a clear distal margin of this ligament as defined by its junction with a pad of fat. If this or other anatomic details fail to provide orientation to critical anatomy, abandon the endoscopic approach in favor of an open carpal tunnel release.

Do not insert the tip of the blade assembly beyond the end of the transverse carpal ligament. This avoids a stretch injury to the small nerve that sends communicating fibers between the ulnar nerve and the median nerve just distal to the carpal tunnel.

Caution

Applying excessive pressure to the endoscope and blade assembly may damage the endoscope’s optics. An unclear image may indicate fogging. Please refer to the Troubleshooting section on page 11.

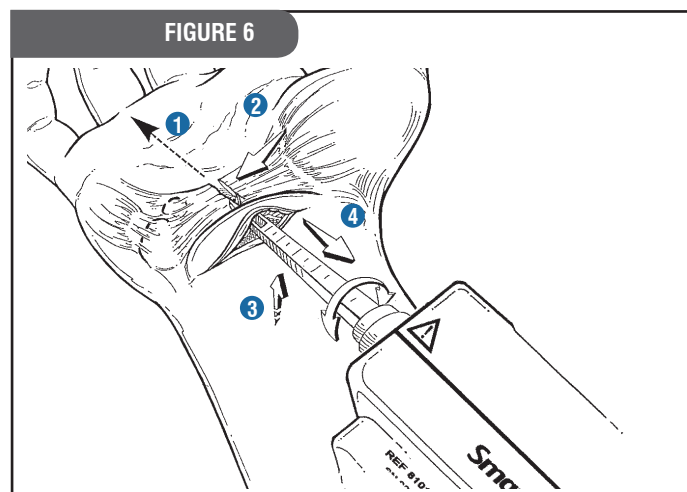
STEP 6

Incising the transverse carpal ligament.

Please study all steps (6, 6A, 6B, 6C and 6D) before proceeding. Assure continued correct positioning, hugging the hook of the hamate and tracking the course of the blade assembly while maintaining ring finger aim. [Figure 6]

Note

The surgeon may choose to release the entire ligament in a single pass; however, there are advantages to releasing the ligament in two stages (distal half then proximal half).



- 1 Aim at ring finger.
- 2 Hug hook of hamate.
- 3 Apply upward pressure on blade assembly to keep window snug against transverse carpal ligament.
- 4 Elevate blade and withdraw instrument to divide the distal one half of the transverse ligament while maintaining steps 1-3. [Figure 6]

STEP 6-A

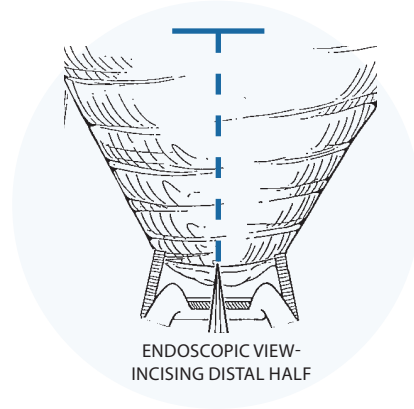
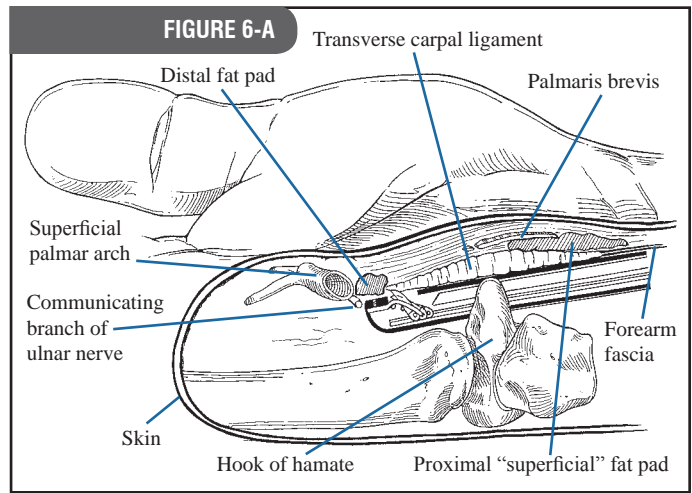
Incising the distal half of the transverse carpal ligament.

Elevate the blade so that it engages the distal margin of the ligament. Firmly but gently withdraw the blade assembly to divide the distal one half of the transverse ligament. Release the trigger to retract the blade. *[Figure 6-A]*

Note

A fat pad lays superficial to the proximal portion of the carpal ligament. Leaving the proximal portion of the ligament intact on the first pass prevents this fat from prolapsing onto the viewing window. This prolapsed fat can compromise the path available for reinserting the blade assembly and can interfere with visualizing the completeness of the ligament release.

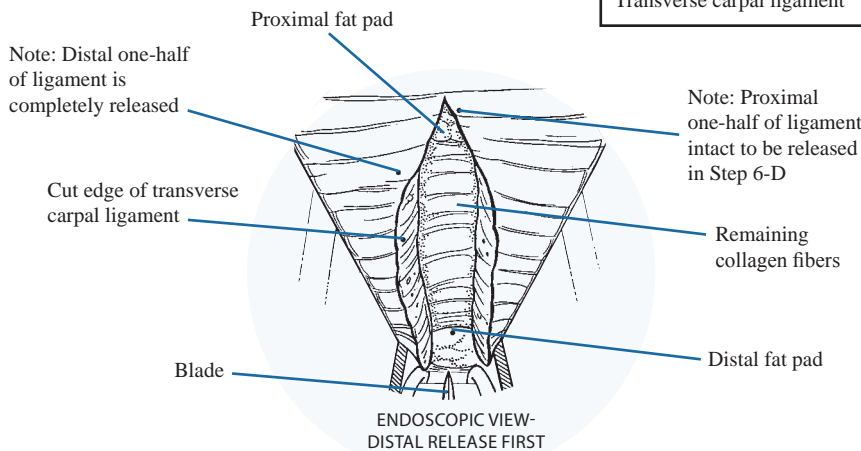
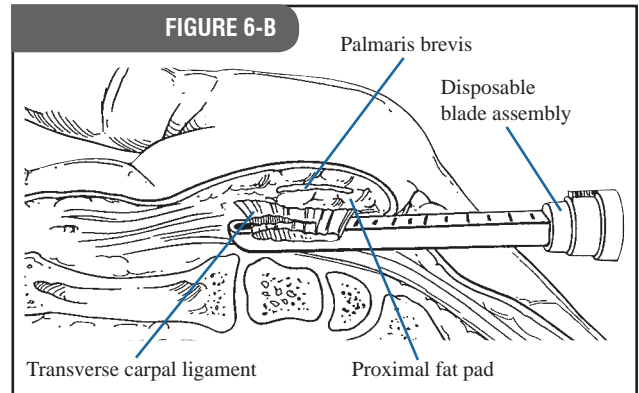
Note that blade is being elevated in both pictures to touch the distal margin of the ligament. Partial elevation is the best way to determine where the blade will engage the ligament.



STEP 6-B

Incising the distal half, continued.

Reposition the blade assembly window to check for a complete release of the distal half of the transverse carpal ligament. Use partial or complete elevation of the blade to selectively divide the remaining collagen fibers with interposed fat and/or muscle. Complete release is indicated by the retraction of the two halves of the ligament in radial and ulnar directions. *[Figure 6-B]*



STEP 6-C

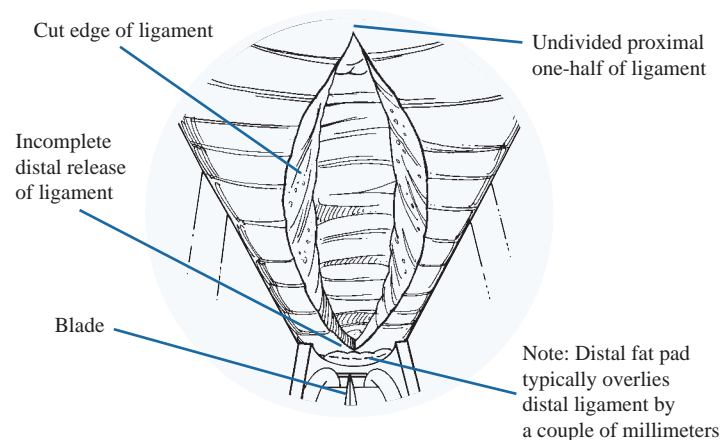
Incomplete release of the distal margin.

In a typical patient, the distal margin of the ligament is defined by its junction with a pad of fat. This fat usually overlaps the deep side of the free margin of the ligament by a couple of millimeters.³ [Figure 6-A]

Occasionally a few fibers of the carpal ligament hidden by this fat will remain undivided after the first pass of the blade. These very distal fibers of ligament overlapped by fat can be visualized and must be divided using partial blade elevations with subsequent passes of the blade assembly. [Figure 6-C]

FIGURE 6-C

Incomplete release of distal margin of ligament where ligament is overlapped by distal fat pad.



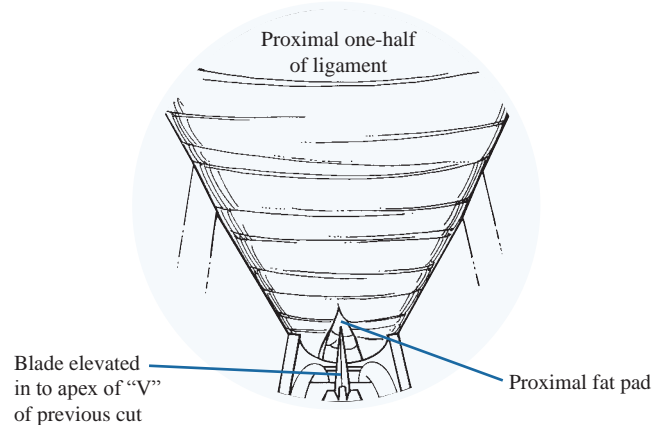
STEP 6-D

Releasing the proximal half of the transverse carpal ligament.

When the distal half of the ligament has been completely released, reposition the viewing window at the proximal extent of the previous cut, elevate the blade into the apex of the "V" and withdraw the device to divide the remaining proximal portion of the ligament. Follow the same precaution: Aim at the ring finger, hug the hook of the hamate and hold the blade assembly snugly against the deep side of the ligament while withdrawing the blade assembly. [Figure 6-D]

FIGURE 6-D

Releasing the proximal portion of the ligament.

**Caution**

Blade extension and retraction should be checked following assembly of the device—before use on the patient. When fully extended, the blade forms an approximate 80-degree angle to the flat surface of the blade assembly and measures approximately 3.5mm in height. If the blade does not extend and retract properly during system checkout, the device should not be used.

Warning

To avoid injury to the median nerve and flexor tendons, it is imperative that the viewing window of the blade assembly be held snugly against the deep side of the transverse carpal ligament.

If the blade fails to retract after the trigger is released, follow these steps for safe removal:

1. Release the blade lock screw while supporting the handpiece. Use the scope to view the blade to ensure blade retraction.
2. If the blade remains elevated, carefully separate the blade assembly from the handpiece, leaving the blade assembly in the carpal tunnel. Use the endoscope to view the blade position as the handpiece is removed from the blade assembly. The blade assembly is left in the carpal tunnel.
3. If the blade has not returned to a retracted position, do not remove the blade assembly from the carpal tunnel through the endoscopic portal. Convert to an open procedure to remove the blade assembly. Inspect the blade assembly to make sure no parts are missing. If a part is missing, take an x-ray of the patient's hand.

STEP 7

Inspecting the incised transverse carpal ligament.

Release the trigger to retract the blade. Reinsert the blade assembly to inspect the completeness of the ligament division. [Figure 7-A]

With the blade retracted, the assembly may be rotated after a complete release to allow the surgeon to inspect the cut edges of ligament.

Complete release - The blade assembly has been reinserted between the two cut edges of the ligament, which have retracted beyond the width of the blade assembly. *Note the fat and transverse fibers of the palmar fascia which remain superficial (palmar) to the divided ligament.* [Figure 7-A]

Complete release - After complete release and blade assembly rotation, each separate cut edge of the ligament will "flop." [Figure 7-B, Viewed with blade assembly rotated 20-degrees]

When additional cuts are necessary, be sure to position the window of the blade assembly in, and/or between, the cut edges of the ligament to avoid injuring the median nerve. Partial blade elevation is frequently useful in completing the ligament division to avoid dividing tissues palmar (superficial) to the ligament.

Incomplete release - A "V" shaped defect is created when the palmar (superficial) fibers of the transverse carpal ligament remain intact. [Figure 7-C]

In addition to the video monitor image, assess completeness of ligament division by several means:

- sensing the reduced "pressure" upon the instrument when it is reinserted in a decompressed carpal tunnel.
- noting the more subcutaneous course of the blade assembly after division.
- palpating the divided ligament with the hamate finders.
- inserting a small right-angle retractor and looking directly inside of the released carpal tunnel at the cut edges of the ligament.

FIGURE 7-A

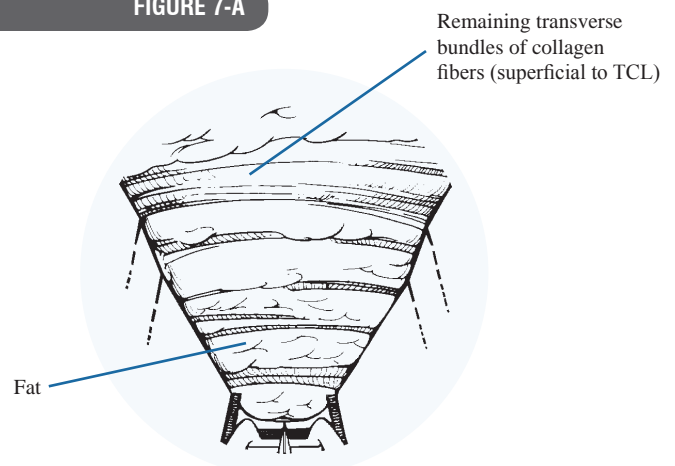


FIGURE 7-B

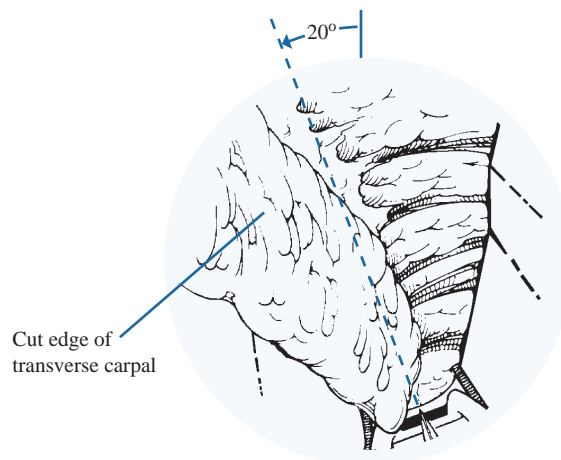
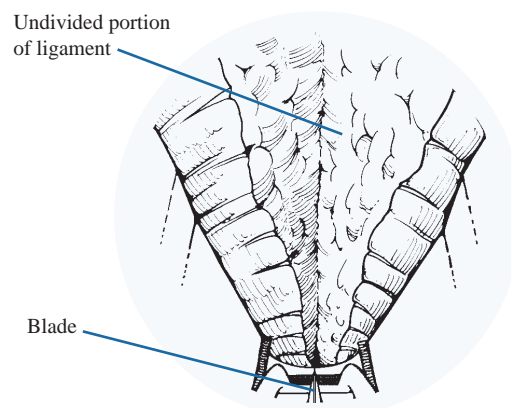


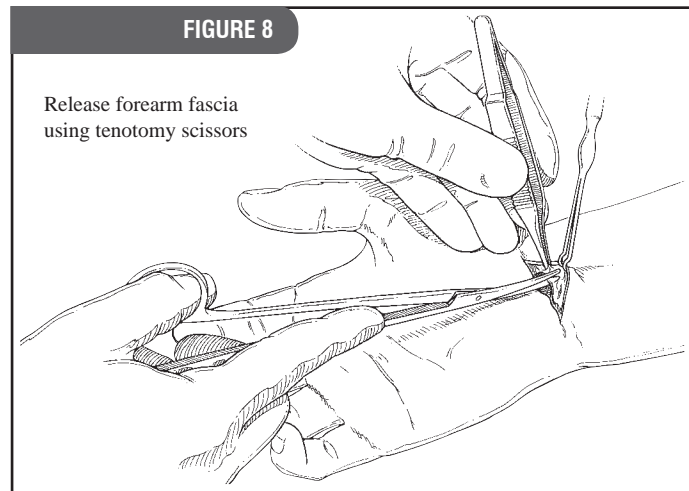
FIGURE 7-C



STEP 8**Releasing the forearm fascia.**

Using tenotomy scissors, release the forearm fascia proximal to the skin incision, taking care to protect the median nerve. This prevents the forearm fascia from acting as a constricting band that could continue to compromise median nerve function.

Before lowering the tourniquet, insert the blade assembly (blade retracted), positioning the viewing window at the distal end of the tunnel to inspect for potentially troublesome arterial bleeders. Release the tourniquet and slowly withdraw the instrument.

**STEP 9****Closing and dressing the wound and wrist.**


The use of an intracuticular suture to close the skin gives the best cosmetic result. Following wound closure, dress the wrist and hand by a method that allows full thumb use and opposition post-operatively.

REFERENCES

- 1 Agee, JM et al. Endoscopic Release of the Carpal Tunnel: A Randomized Prospective Multicenter Study. *Journal of Hand Surgery*. 1992; 17(6):987-995.
- 2 Agee, JM et al. Endoscopic Carpal Tunnel Release: A Prospective Study of Complications and Surgical Experience. *Journal of Hand Surgery*. 1995; 20A(2):165-171.
- 3 Rotman, MB, Manske, PR. Anatomic Relationships of an Endoscopic Carpal Tunnel Device to Surrounding Structures. *Journal of Hand Surgery*. 1993; 18A(3):442-450.


Additional Material Available from MicroAire

SmartRelease™ ECTR Instructions for Use
 Assembly, operation and maintenance guide for the SmartRelease™ ECTR
 (Order: REF: IM-ECTR-IFU)



SmartRelease™ ECTR Surgeon Training Binder
 Surgical skills training guidelines for surgeons learning to perform the MicroAire endoscopic procedure
 (Order: LIT-ECTR_SurgeonBinder)




My Carpal Tunnel 
 Patient-information brochure about options for the treatment of carpal tunnel syndrome
 (Order: LIT-CTRS_Patient)



SmartRelease™ ECTR Cleaning Chart
 Cleaning and sterilization wall chart for the MicroAire SmartRelease™ ECTR® System
 (Order: LIT-ECTR_Chart_11x17)



MyCarpalTunnel.ORG 
 Web-based patient information about options for the treatment of carpal tunnel syndrome
 (www.mycarpaltunnel.ORG)



MICROAIRE®

Phone 800.722.0822 MicroAire Surgical Instruments
 + 434 975 8000 1641 Edlich Drive
 Charlottesville, VA 22911
 USA
 Fax 800.648.4309
 + 434 975 4131 www.microaire.com

SmartRelease™
 Endoscopic Carpal Tunnel Release **ECTR**



A COLSON ASSOCIATE