

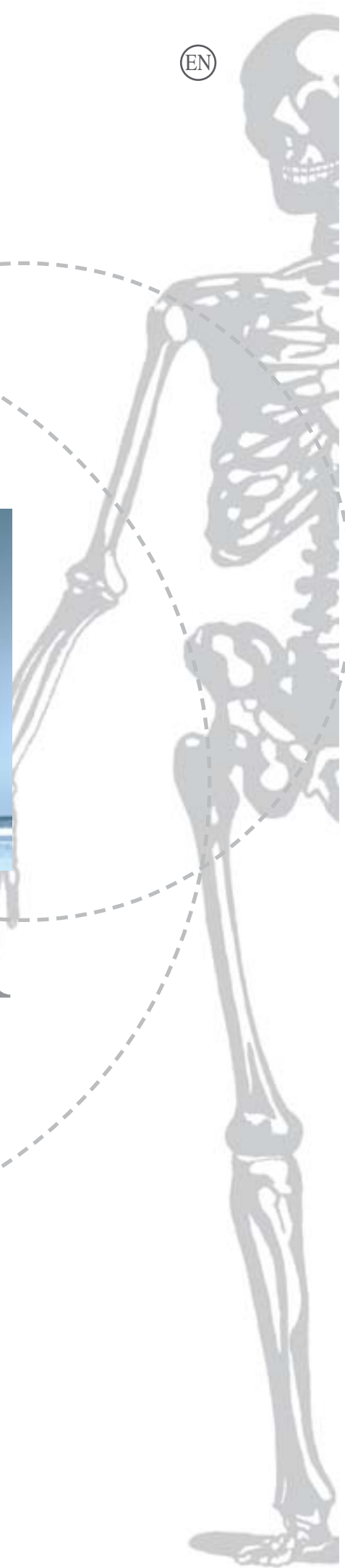orthopaedics

a great idea



SPACER

- » spacer G
- » spacer K





Our company, which today boasts over twenty five years of history, began working in the biomechanical sector specializing in high-technology superficial treatments, principally on screws for surgical use.

Subsequently, our work diversified with our entrance into the chemico-pharmaceutical sphere, concentrating on the development of innovative acrylic resins for orthopedics. TECRES is ISO 9001 and ISO 13485 certified, and authorized by the Italian Health Ministry to manufacture antibiotics.

It also has ministerial authorization from over 40 countries to sell its products abroad.



SPACER

Tecres spacers are temporary implantable devices, indicated to replace temporarily a joint prosthesis removed as a result of a septic process.

The spacers are made of gentamicin bone cement and they release antibiotic into the surrounding tissues to help the treatment of infection.

The spacer have standardised mechanical and pharmacological properties.

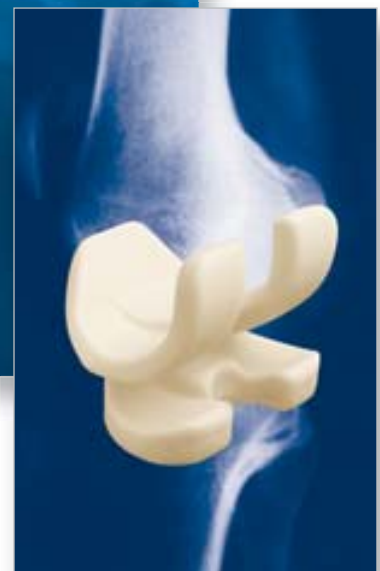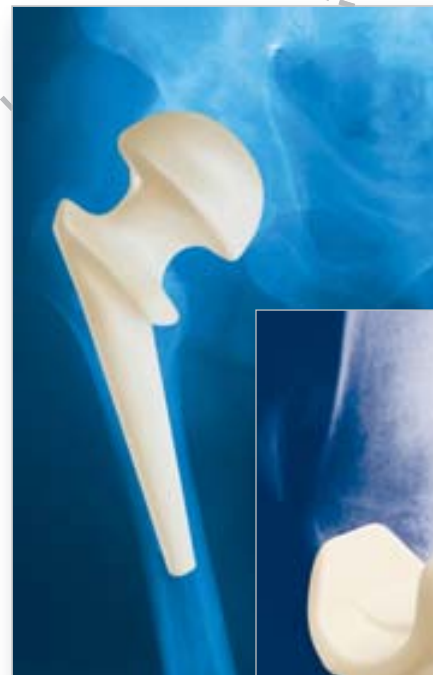They have to be removed maximum 6 months after their implant.

The spacers allow:

- » **Maintenance of joint space and mobilisation;**
- » **Effective in situ release of gentamicin antibiotic;**
- » **Deambulation with partial weight-bearing*;**
- » **Facilitation of definitive re-implant surgery;**
- » **Reduction of functional recovery time after the intervention of definitive revision.**

* Partial weight-bearing must be assessed on an individual basis in relation to the anatomic condition, bone trophism and clinical conditions of the patient during rehabilitation stages.

In particular, one should avoid the risk that excessive weight-bearing or forced mobilization cause the structure of the spacer to damage the bone tissue.



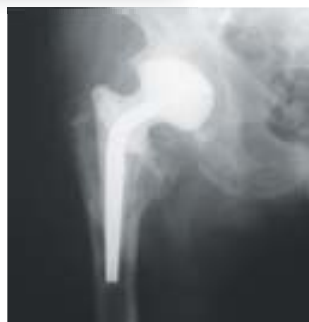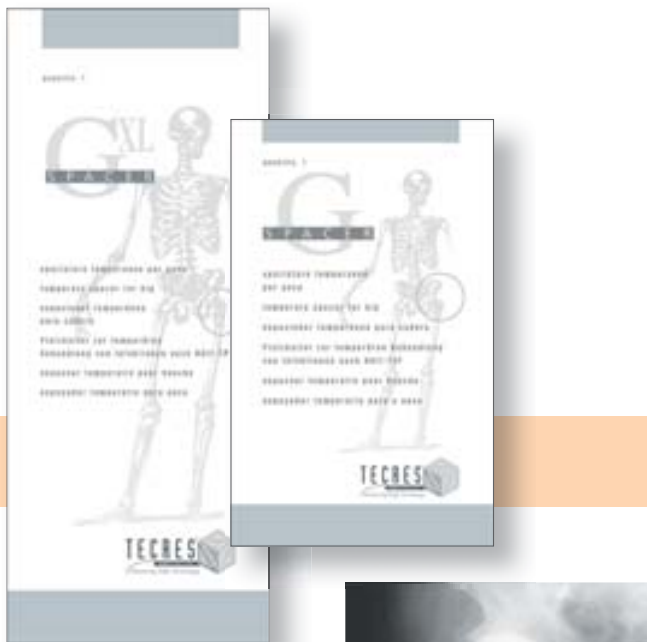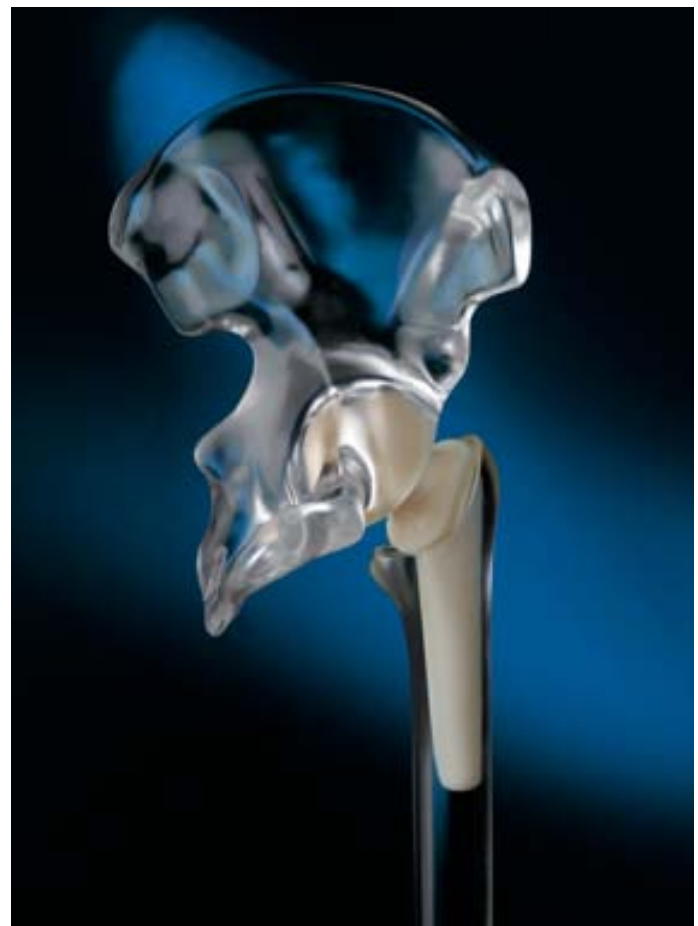G SPACER

DESCRIPTION

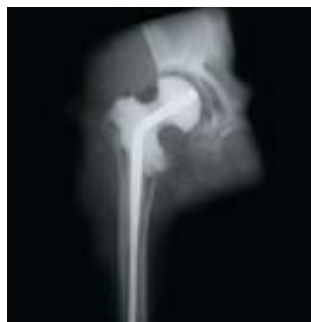Spacer-G resembles a femoral prosthesis.

It is made of a load-bearing structure in AISI 316L stainless steel coated with gentamicin bone cement. Spacer-G is inserted into the femoral canal and the acetabular cavity following removal of the previous implant.

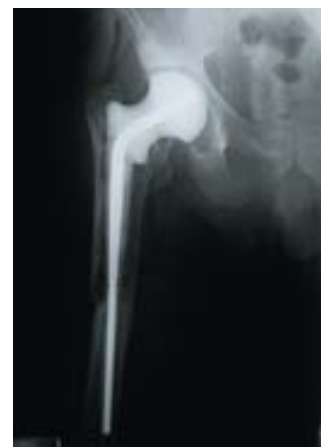When a distal anchorage is required - in absence of proximal support, in presence of large metaphyseal defects or after a trans-femoral approach - the extra-long stem version (XL) is indicated.



X-ray overview Spacer-G



X-ray overview proximal cementation Spacer-G-XL



X-ray overview Spacer-G-XL

SURGICAL TECHNIQUE

All access routes to the hip can be used for insertion of the device. Clean the host site with Ringer solution or saline before inserting Spacer-G; in particular eliminate, wherever possible, all residues of cement left by the previous implant.

Fit the stem of Spacer-G into the diaphyseal canal of the femur, making sure that:

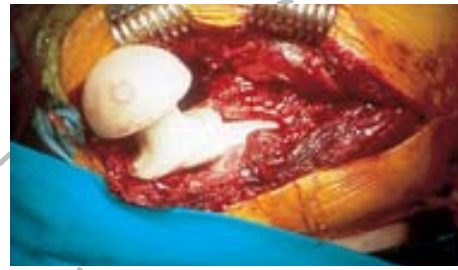- the protruding edge of the Spacer-G rests on the residual margin of the cortex resected at the inter-trochanteric level;
- the tip of the stem does not rest on any obstacles present inside the diaphyseal canal.

Reduce the head towards the acetabular cavity.

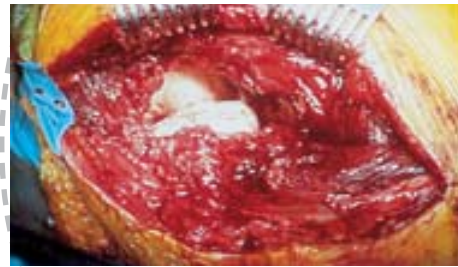When the bony acetabular roof is well-preserved, it may provide direct support for the head of Spacer-G.

In case of instability a proximal cementation of the neck may be performed.

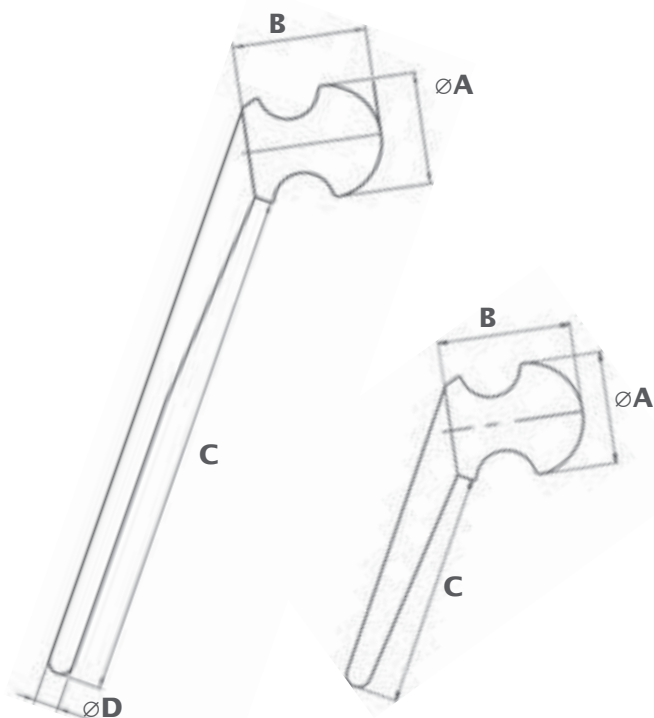
If large areas of bone resorption are evident, it is possible to take advantage of the residual support of the acetabular roof on the neck of Spacer-G, which is specially profiled for this purpose.



Spacer-G insertion



Spacer-G reduction



ORDERING INFORMATION AND DIMENSIONS

| REF. | A (mm) | B (mm) | C (mm) | D (mm) | Gentamicin (g) |
|------------------|--------|--------|--------|--------|----------------|
| SPC46/G | 46 | 54,5 | 96 | - | 1,1 |
| SPC54/G | 54 | 60 | 94 | - | 1,9 |
| SPC60/G | 60 | 73 | 98 | - | 3,0 |
| SPC46/GXL | 46 | 54,5 | 211 | 10 | 1,3 |
| SPC54/GXL | 54 | 60 | 209 | 10,5 | 2,1 |
| SPC60/GXL | 60 | 73 | 211 | 11 | 3,2 |

To select the right size to be implanted there are the templates and the trial spacers available.

| REF. | DESCRIPTION |
|----------------|-----------------------------------|
| SPG03 | Spacer-G Trial (three-size set) |
| SPG03XL | Spacer-GXL Trial (three-size set) |

K SPACER

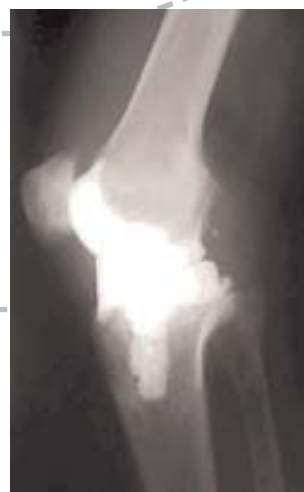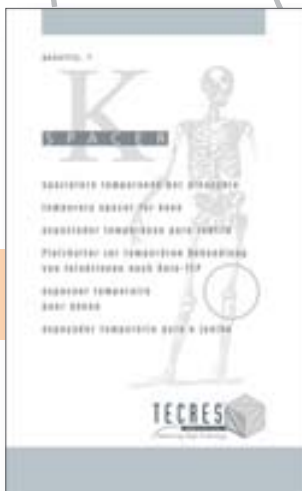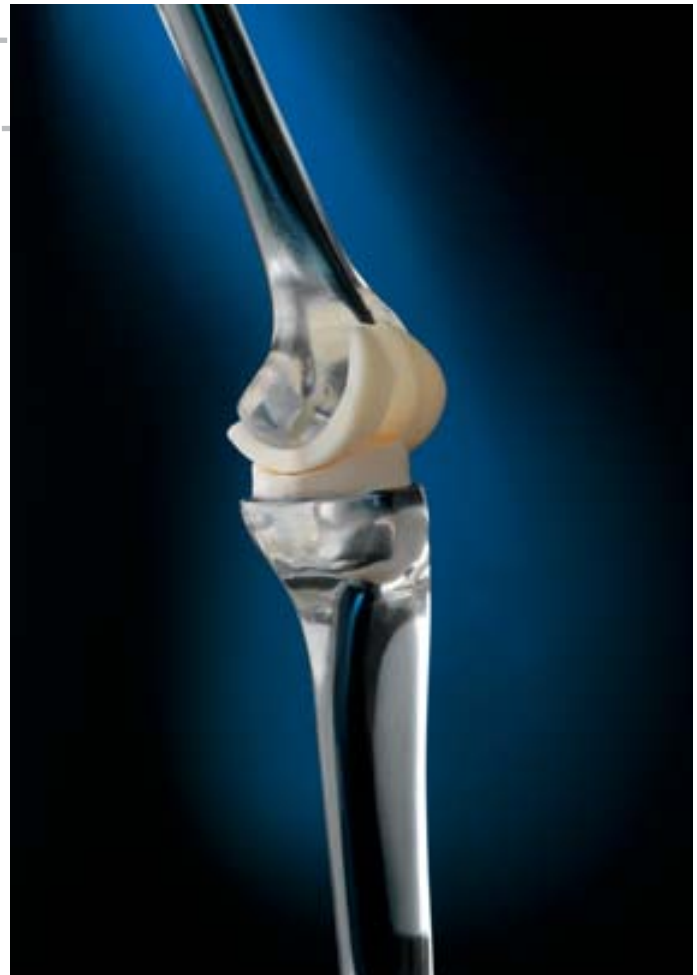DESCRIPTION

Spacer-K resembles an ultra-congruent condylar knee prosthesis. It consists of two articulating independent elements.

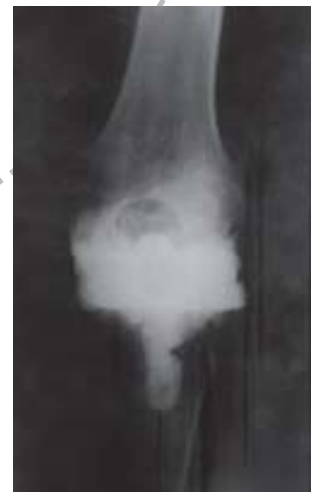The tibial component has a flat base upon which the femoral component articulates.

Spacer-K is applied on the femoral condyles and on the tibial plate following removal of the previous implant.

Both components are to be fixed with bone cement.



Post-surgery x-ray overview



Lateral post-surgery Spacer k overview

SURGICAL TECHNIQUE

Spacer-K is generally applied using the medial para-patellar route.

Clean the host site with Ringer solution or saline (pulsed lavage) before inserting Spacer-K. In particular eliminate, wherever possible, all residues of cement left by the previous implant.

The most suitable size is selected on the basis of:

- dimensions of the removed implant;
- bone defect;
- ligamentous apparatus state;
- flex and extension spaces.

Once the size has been chosen, it is advisable to apply both components without cement and reduce the joint to evaluate stability and joint function.

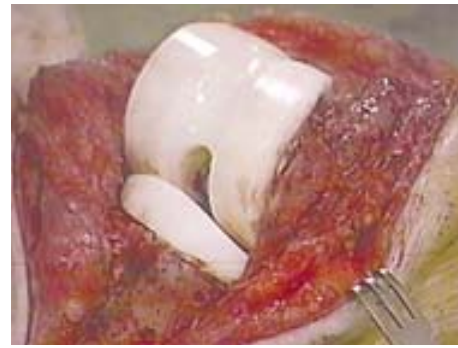
The two components must be fixed with bone cement.

Apply the femoral part first, and wait for the polymerisation of the cement, then proceed with the application of the tibial part, avoiding in either cases that excess cement adheres to the articulating surfaces.

Reduce eventually the joint before the cement of the tibial part has cured to allow for the self-centering of the tibial component in relation to the femoral one, and keep in extension till complete polymerisation.

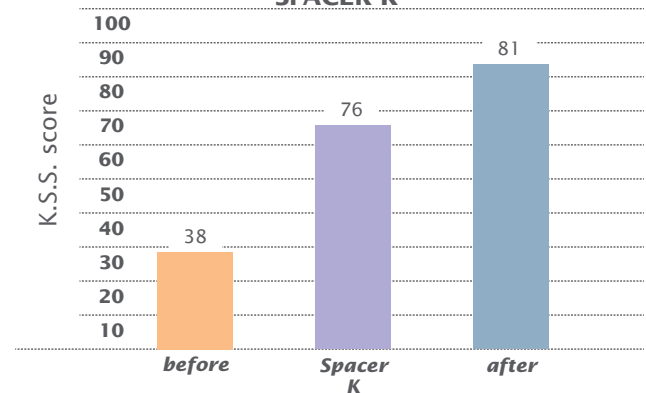
Clean the area from any debris.

When the suture and the reconstruction of the extensor apparatus has been completed the knee must be stable, but not too tight, and have a joint excursion ranging from 0° and 90°.



Spacer-K reduction

FUNCTIONAL OUTCOME USING SPACER K



Preformed articulating knee spacer in two-stage revision for the infected TKA

Castelli C, Ferrari R

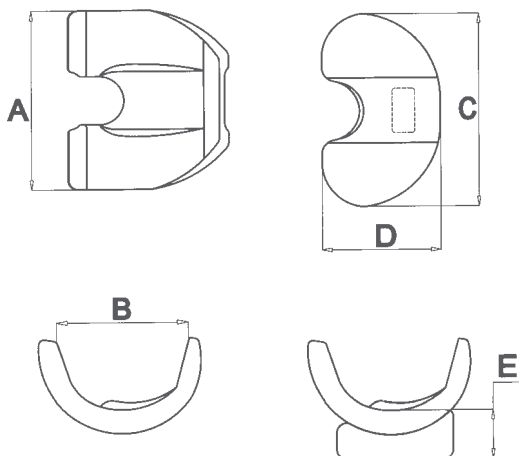
Proceedings of 12th ESSKA 2006, Innsbruck P-326

| Range of motion (ROM) of the knee | |
|-----------------------------------|-----|
| Pre-op | 59° |
| Between stages | 77° |
| At last FU after 2nd stage | 94° |

Int Orthop. 2005 Oct;29(5):305-8.

Pre-formed articulating knee spacer in two-stage revision for the infected total knee arthroplasty.

Pitto RP, Castelli CC, Ferrari R, Munro J



ORDERING INFORMATION AND DIMENSIONS

| REF. | A (mm) | B (mm) | C (mm) | D (mm) | E (mm) | Gentamicin (g) |
|------------------|--------|--------|--------|--------|--------|----------------|
| SPK6054/G | 54 | 40 | 60 | 36 | 16 | 0,9 |
| SPK7064/G | 64 | 47 | 70 | 42 | 17 | 1,3 |
| SPK8074/G | 74 | 54 | 80 | 48 | 18 | 1,8 |

To select the right size to be implanted there are the templates and the trial spacers available.

| REF. | DESCRIPTION |
|--------------|---------------------------------|
| SPK03 | Spacer-K Trial (three-size set) |

BIBLIOGRAPHY

B1C074 rev 04/08

Affatato S, Mattarozzi A, Taddei P, Robotti P, Soffiatti R, Sudanese A, Toni A

Investigations on the wear behaviour of the temporary PMMA-based hip Spacer-G — *Proc Inst Mech Eng [H]*. 2003;217(1):1-8

Baleani M, Traina F, Toni A

The mechanical behaviour of a preformed hip spacer
Hip International /Vol.13 n°3, 2003 / pp.159-162

Bertazzoni Minelli E, Benini A, Magnan B, Bartolozzi P

Release of gentamicin and vancomycin from temporary human hip spacers in two-stage revision of infected arthroplasty
J. Antimicrob. Chemother. 2004 53: 329-334

Bertazzoni Minelli E, Benini A, Magnan B, Bartolozzi P

Release of antibiotics and inhibitory activity in drainage fluids following temporary spacer implants in two-stage revision surgery — *ECCI Florence (ITA)* - Oct. 2005

Burnett RS, Kelly MA, Hanssen AD, Barrack RL

Technique and timing of two-stage exchange for infection in TKA. — *Clin Orthop Relat Res.* 2007 Nov;464:164-78. Review

Casalino-Finocchio G, Riccio G, Sandrone C et al.

Two-stage reimplantation for severe prosthetic device infections using antibiotic-impregnated cement spacer
EBJIS Lubiana (SLO) - May 2005

Castelli C, Ferrari R

Strategy and Results of two-stage treatment for the Infected TKA
AAOS Chicago (USA) - March 2006

Castelli C, Martinelli R, Ferrari R

Preformed all-cement knee spacer in two-stage revision for infected knee replacement: early clinical results
EFORT Helsinki (FIN) - June 2003

Castelli C, Robotti PF, Calonego G

Preformed all-cement knee spacer in two-stage revision for infected knee replacement: mechanical and pharmacological behaviour — *SICOT San Diego (USA)* - Aug. 2002

D'Angelo F, Negri L, Zatti G, Grassi FA

Two-stage revision surgery to treat an infected hip implant. A comparison between a custom-made spacer and a pre-formed one. — *Chir Organi Mov.* 2005 Jul-Sep;90(3):271-9.

Evans RP

Successful treatment of total hip and knee infection with articulating antibiotic components: a modified treatment method.
Clin Orthop Relat Res. 2004 Oct;(427):37-46

Magnan B, Regis D, Biscaglia R, Bartolozzi P

Preformed acrylic bone cement spacer loaded with antibiotics: use of two-stage procedure in 10 patients because of infected hips after total replacement
Acta Orthop Scand 2001 Dec;72(6):591-4

Magnan B, Regis D, Facci E, Modena M, Bartolozzi P

A preformed antibiotic-loaded acrylic cement spacer in two-stage revision of infected total hip arthroplasty
AAOS New Orleans (USA) - Feb. 2003

Marchesini A, Martinotti L, Klumpp R

Infekt nach Prothesenimplantation im hohen Alter: Casereport über die Behandlung von 2 Patienten mit "Spacer" (Platzhalterprothese) und antibiotischem Zement
DGU Berlin (GER) - Nov. 2003

García S, Soriano A et al.

The use of articulated spacer hip for the treatment of total hip arthroplasty infection — *EBJIS Corfu (GR)* - Corfu Sept. 2007

Martínez JC, Soriano A, García S et al.

The use of articulated spacer knee between first and second stage of treatment of total knee arthroplasty infection
EBJIS Corfu (GR) - Corfu Sept. 2007

Meani E, Romanò C

Strategy and Results of two-stage treatment for Infected THA
AAOS Chicago (USA) - March 2006

Meani E, Romanò C, Crosby L, Hofmann (Eds.)

Infection and local treatment in orthopaedics surgery
Springer-Verlag - 2007 — ISBN: 978-3-540-47998-7

Mutimer J, Lovering A, Gillespie G, Porteous A

Measurement of in vivo intra-articular gentamicin levels from antibiotic loaded articulating spacers — *EFORT Florence (ITA)* - May 2007

Pitto RP, Castelli CC, Ferrari R, Munro J

Pre-formed articulating knee spacer in two-stage revision for the infected total knee arthroplasty — *Int Orthop.* 2005 Oct;29(5):305-8

Pitto RP, Spika IA

Antibiotic-loaded bone cement spacers in two-stage management of infected total knee arthroplasty — *Int Orthop.* 2004 - Jun; 28(3):129-33.

Romanò C, Romanò D, Meani E

Two-stage non-cemented revision of infected total hip prosthesis
ISTA Oxford (UK) - Sept. 2002

Salvador J, Matamala A, Asunción J, Ferrer H

Utilización de espaciador en infección de artroplastia total de cadera. — *SECA Gijón (ESP)* - June 2003

Spika I, Castelli C, Matamala A, Federici A et al.

Articulating spacer in two-stage revision of the infected total knee replacement — *AOA Adelaide (AUS)* - Oct. 2003 — *JBJS(Br), Orthopaedic Proceedings*, Vol 86-B, Issue SUPP IV, 471-2.

Takahira N, Itoman M, Higashi K et al.

Treatment outcome of two-stage revision total hip arthroplasty for infected hip arthroplasty using antibiotic-impregnated cement spacer — *J Orthop Sci.* 2003;8(1):26-31.

Villa T, Carnelli D

Experimental evaluation of the biomechanical performances of a PMMA-based knee spacer. — *Knee* 2007 Mar;14(2):145-53



TECRES S. p. A.
Via A. Doria, 6 - Sommacampagna - Verona (Italy)
tel. +39 045 92 17 311 - fax +39 045 92 17 330
www.tecres.it - info@tecres.it

distributed by

